



By your veterinary ophthalmologist

Dr. Franck Ollivier
DMV, Ph.D, Dipl ACVO et ECVO
Veterinary ophthalmology specialist (FR)

Hypertensive retinopathy

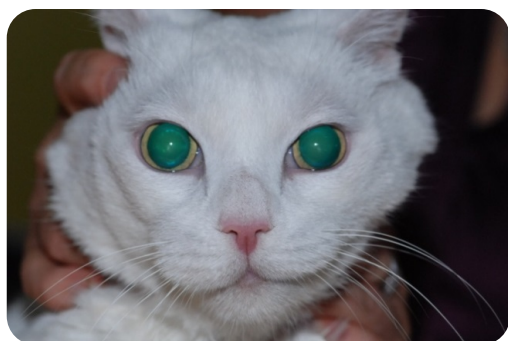What is hypertensive retinopathy?

Hypertension, or high blood pressure, can be a spontaneous (primary) condition, but is usually associated with kidney disease or hyperthyroidism. We always recommend a complete blood count (CBC), serum profile / panel, urinalysis and a thyroid (T4) level, if it has not already been recently performed. It is very common to diagnose hypertension only after changes in vision have occurred, because while this medical condition is serious, it is not painful and may not cause any other changes in the pet's behavior.

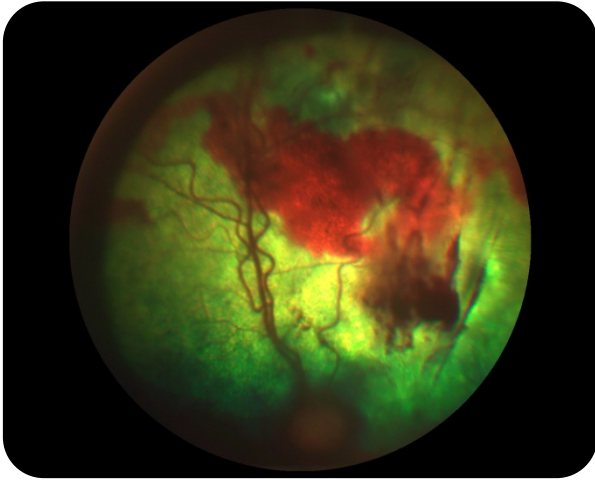
Hypertensive retinopathy, which can include small to extensive areas of retinal detachments and hemorrhage, is often controllable with oral medications. However, systemic hypertension is rarely curable and lifelong treatment is necessary.

Eyes with complete (total) retinal detachments, and especially those with significant hemorrhage, tend to be associated with a poorer visual prognosis. Any changes in vision may be permanent. It is important to control blood pressure as much as possible due to the damage that can be caused to the heart and kidneys, as well as the retinas.

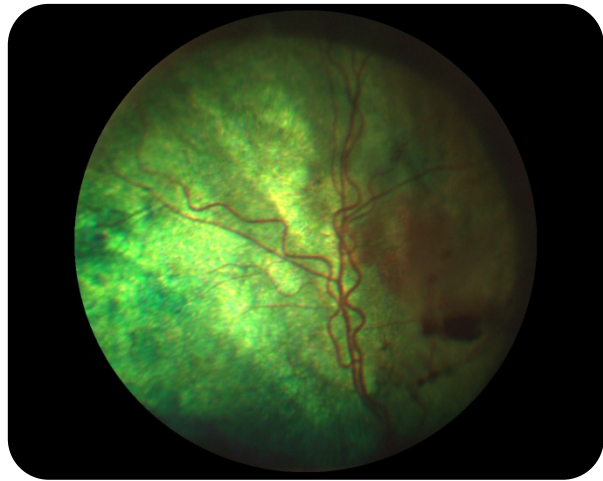
Regular monitoring of blood pressure and blood testing with your family veterinarian is crucial for optimal long-term management of this condition.



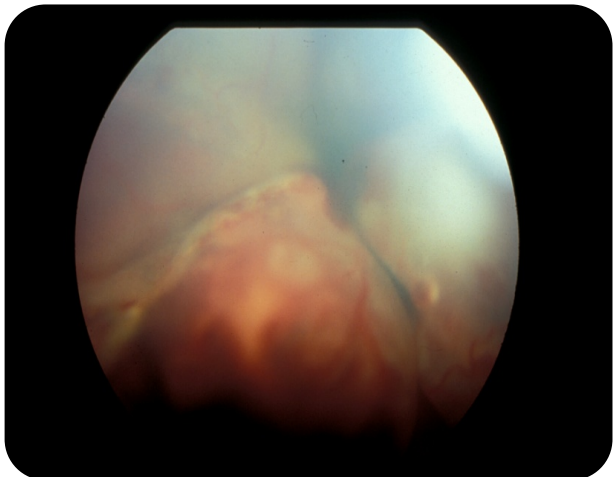
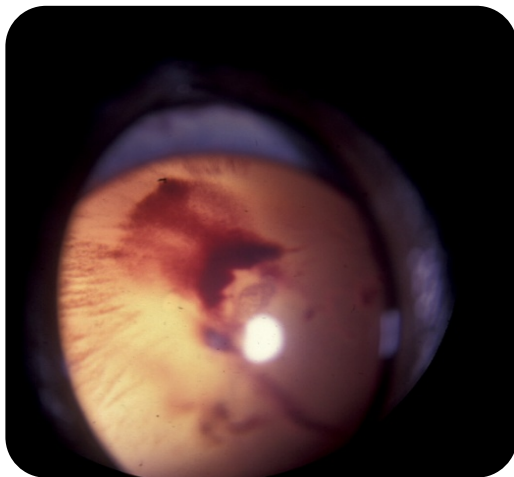
An aged cat, blind, with a systemic hypertension and a secondary hypertensive retinopathy: note the complete dilation of the pupil (we can almost not see his yellow irises).



Picture of the fundus (retina) of the same cat: note the important hemorrhages.



Picture of the fundus (retina) of the same cat after 10 days of medical treatment for systemic hypertension: note that most of the hemorrhages have resolved.



Picture of the fundus (retina) of two with a systemic hypertension with a secondary hypertensive retinopathy: the retinopathy is more severe in these cases as we can observe not only hemorrhages but also retinal detachment (the white velum on the pictures).