



By your veterinary ophthalmologist

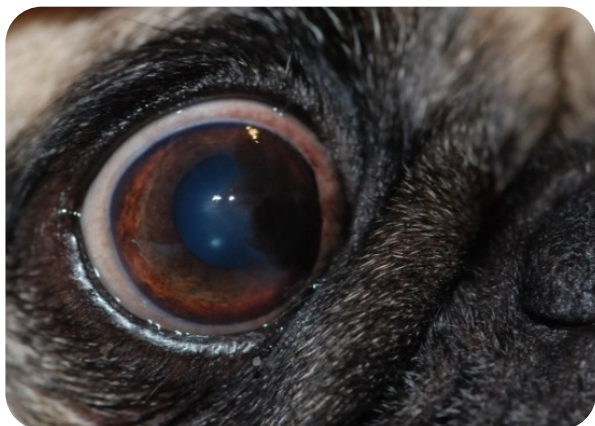
Dr. Franck Ollivier
DMV, Ph.D, Dipl ACVO et ECVO
Veterinary ophthalmology specialist (FR)

Medial canthoplasty

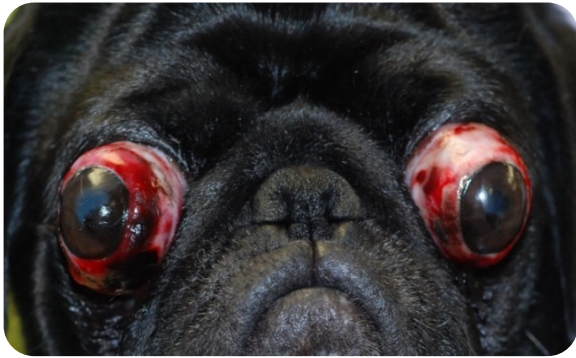
Dogs with large flat faces (brachycephales) are at high risk of getting eye problems during their life, and sometimes very early in time, because of various reasons due to their conformation. These factors include a big ocular globe (therefore more exposed), a shallow orbital cavity (therefore the globe is less protected and can slip out from the bone socket), a short nose with skin folds (therefore the hair rub against the cornea), an hairy caruncle (small bump with some hair in the space close to the nose, therefore hair are rubbing against the cornea), a large eyelid opening (therefore the globe is more exposed).

It is therefore easy to understand that these dogs represent the breeds that are predisposed to have the following eye problems: pigmentary keratitis (superficial pigment deposition), dryness of the eye, proptosis of the globe (globe getting out from its socket) and corneal ulcers (wound of the cornea, frontal part of the eye that is transparent).

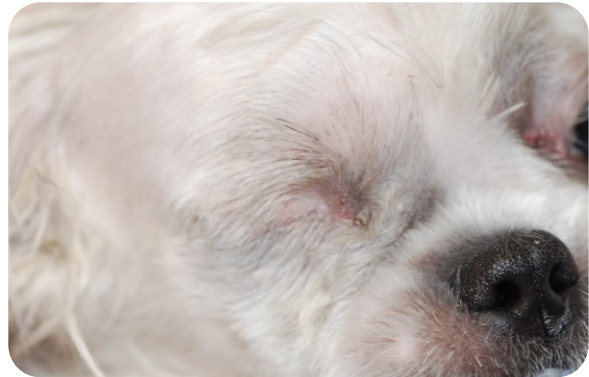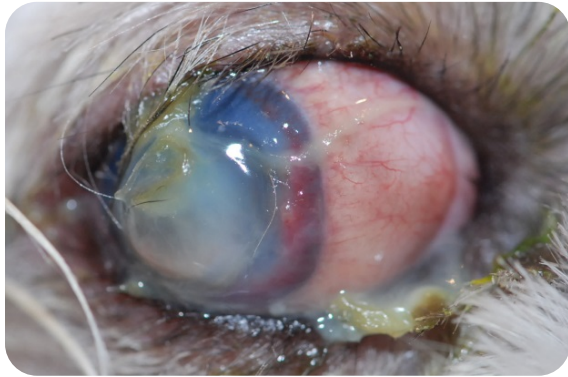
These ocular conditions can not only be painful for the animal but they can lead to the loss of vision.



An example very common in pugs: large palpebral opening exposing a large area of the sclera (white external part of the eye), hair from the nasal folds can rub against the cornea leading to superficial brown pigment deposition in the medial aspect of the cornea. This is defined as pigmentary keratitis.



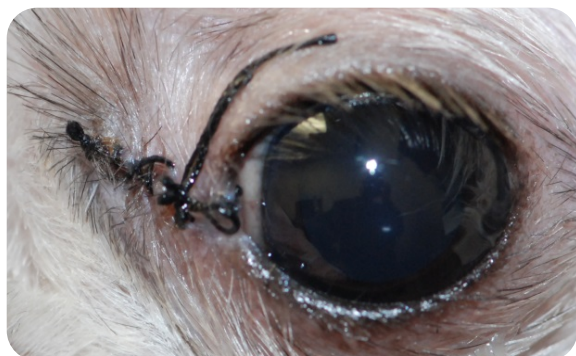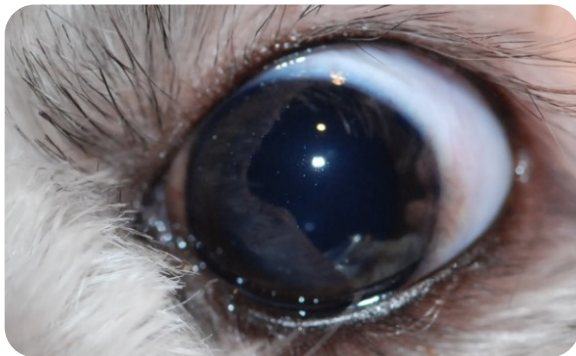
Another example in a pug: large palpebral opening that does not protect the globe adequately and therefore they got displaced forward during a frontal choc. This dislocation of the eye is called proptosis (in this case due to the pet hit by a car).



Medial canthoplasty performed on the left eye of the 9 month Shih Tzu that lost its right eye from an infected ulcer.

Left eye before surgery

Left eye just after the procedure



Left eye before surgery

Left eye 14 days after surgery

It is easy to understand the 3 benefits of this short and simple surgical procedure that can be done by a veterinary ophthalmologist:

- Reduction of the risk of dislocation of the globe (globe proptosis) to almost zero by reducing the palpebral opening length.
- Reduction of risk of pigmentary deposition on the cornea (pigmentary keratitis) to almost zero by closing the eyelid in the corner close to the nose (medial canthoplasty)
- Reduction of the risk of corneal wound (corneal ulcers) quite considerably by reducing the palpebral opening and therefore protecting the cornea better.

In conclusion, the bilateral medial canthoplasty in puppy or young dogs from brachycephales (short nose / flat faces) breeds such as Pekingese, Shih tzu, Lhasa Apso, French bulldog, Pug, Boston Terriers, Cavalier king charles is an effective surgical treatment to prevent many possible ocular conditions than can occur in the lifetime of these dogs.

