



By your veterinary ophthalmologist

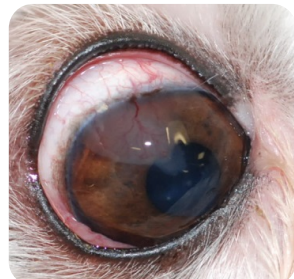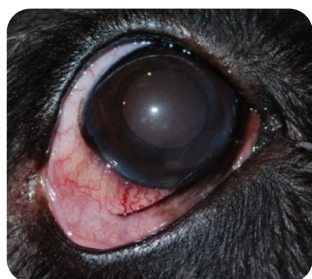Dr. Franck **Ollivier**  
DMV, Ph.D, Dipl ACVO et ECVO  
Veterinary ophthalmology specialist (FR)

## Nodular granulomatous episcleritis (NGE)

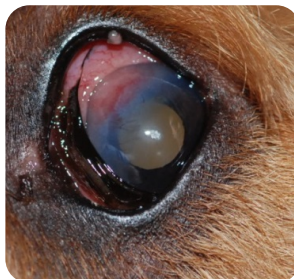
### What Nodular granulomatous episcleritis (NGE)?

Nodular granulomatous episcleritis (NGE) is an immune-mediated (inflammatory) disease that affects the sclera, cornea and nictitating membrane. The condition is diagnosed most commonly in Collies, Cocker Spaniels, and related breeds. Usually a combination of topical and oral anti-inflammatory and / or immunosuppressant medications is prescribed to treat the condition. Once the episcleritis is in remission, the medications are slowly tapered over a period of several months to minimize the risk of recurrence. In severe cases surgical debulking of the nodules with cryotherapy (freezing procedure) may be necessary to induce remission.

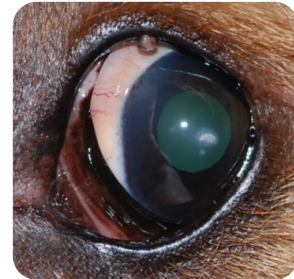
A treatment regimen using oral tetracycline and niacinamide (Vitamin B3) over a period of weeks to months has also been described but the results in causing regression of are variable.



Examples of 2 eyes with NGE



Initial aspect of an eye with NGE



Same eye 3 weeks post anti-inflammatory treatment